
Thyroid Disease: Cameron Ch: 121-125

Mark Keldahl M.D.
Surgery Resident Conference
2/27/08



THYROID NODULE

Thyroid Nodule

- United States Prevalence 2-4%
- History (Malignancy RF)
 - Age (>40)
 - Male gender
 - h/o radiation
 - +FH (MEN 2 A/B)
 - Gardner's, Cowden dz
- Exam (Malignancy RF)
 - ↑ # nodules
 - ↑ size
 - Irregular shape
 - Firm
 - Immobile

Thyroid Nodule

- Diagnostic Evaluation
 - FNA – GOLD STANDARD
 - U/S
 - Microcalcifications
 - Intranodular vascular markings
 - Irregular borders
 - Cytology
 - 1948, cytopathologic, not histopathologic
 - NO info re vascular or lymphatic invasion
 - TFT's
 - Majority of patients are euthyroid
 - Thyroid radioisotope scan

Thyroid Nodule

FNA results

- Benign (70%)
 - Adenomatoid or hyperplastic
 - Hashimotos
 - Colloid cyst
- Malignant (5%)
 - Papillary
 - Medullary
 - Anaplastic
 - Lymphoma
 - metastatic
- Suspicious (10%)
 - follicular neoplasm
 - Hurthle
 - Suspicious for papillary or follicular variant of papillary CA
- Non diagnostic or Inadequate (15%)

Thyroid Nodule

- Benign:
 - Follow clinically, watch for ↑ size, re FNA
 - Approx. 1% convert to malignancy
 - Role of thyroid hormone therapy
- Malignant
 - Surgery
- Suspicious
 - Lobectomy w isthmusectomy
 - Total thyroidectomy if ↑ clinical suspicion
- Inadequate



NONTOXIC GOITER

Nontoxic Goiter

- Any benign enlargement of the thyroid
- Etiology:
 - Worldwide endemic #1: Iodine deficiency 12% of world
 - U.S. : non-endemic 3-4% of population
 - Radiation
 - Environmental goitrogens
 - Dyshormonogenesis
 - Thyroid growth factors
- Most common type: Multinodular goiter
 - Female > M
 - Nodules outgrow blood supply, necrosis, fibrosis

Goiter

- Diagnosis:
 - Painless enlargement
 - Less common: pressure, phlegm, dysphagia, pain radiate to ear, voice change
 - Rare: dyspnea, orthopnea, hoarseness, stridor
 - Rapid growth, firm: suspicious for CA
- Non OP TX
 - Suppressive therapy
 - Not for functioning nodules
 - Radioactive Iodine
 - Dependent on functioning thyroid tissue
 - Some say suboptimal for multinodular goiter
 - Good for poor surgical candidates

Goiter

- Evaluation
 - Thyroid function tests
 - Majority euthyroid
 - If hyper/hypo: check thyroidantibodies
 - FNA
 - 70% are benign (1% false neg rate)
 - 4% malignant (1% false + rate)
 - 20% indeterminant
 - U/S
 - Solid vs cystic
 - CXR, CT, MRI
 - Radioactive iodine scan
 - Hot: 99% benign
 - Cold: 20% malignant

Goiter:

Operative Indications

- Symptomatic: airway, esophagus, SVC
- Enlargement despite non op RX
- BX proven or suspicious for malignancy
- Tracheal deviation or compression on imaging
- Substernal goiter
- Cosmetic deformity/patient preference

Goiter:

Operative options

- Lobectomy & isthmusectomy
- Near total thyroidectomy
 - Leave approx 5 g tissue
- Bilateral subtotal
 - High recurrence
 - Avoid thyroid supplement



THYROID CANCER

Thyroid Cancer

- 1.5% of all CA in U.S.
- 95% of all endocrine CA in U.S.
- 74% are in women
- 90% are differentiated type
 - favorable prognosis
- <10% of thyroid nodules are malignant

Presentation of Thyroid CA

- Most asymptomatic with thyroid nodule
- Less common
 - Hoarseness
 - Dysphagia
 - Dyspnea
 - Cough
 - Choking spells
 - Cervical lymphadenopathy

Physical Exam

- Fixed or mobile
- Other nodules?
- Hoarseness
 - Laryngoscopy – cord paralysis
- FNA

Thyroid Nodule - FNA

- Benign:
 - Follow clinically, watch for ↑ size, re FNA
 - Approx. 1% convert to malignancy
 - Role of thyroid hormone therapy
- Malignant
 - Surgery
- Suspicious
 - Lobectomy w isthmusectomy
 - Total thyroidectomy if ↑ clinical suspicion
- Inadequate

Classification of Thyroid CA

- Tumors of follicular cell origin
 - Differentiated
 - **Papillary** 75%
 - **Follicular** 10%
 - **Hurthle Cell** 5%
 - Undifferentiated
 - **Anaplastic** 5%
 - Parafollicular or C-cell origin
 - **Medullary** 5%
 - Other
 - **Lymphoma** <1%

Papillary CA

- Most common malignant thyroid tumor
- Types:
 - Pure papillary
 - Follicular
 - Tall-cell
 - Columnar cell
 - Oxyphylic
 - Difuse sclerosinig
 - Encapsulated histologic variants
- 90% of radiation induced thyroid CA

Histology

- Psammoma bodies
- Intranuclear grooves
- Cytoplasmic inclusions
- Multicentric 30-50%

- **Lymphatic Spread**
 - Lung and bone common mets

Operation – some debate

■ Lobectomy w isthmusectomy

- <1 cm size
- No systemic or lymphatic mets
- Low risk for recurrence
 - Recurrence 5%
 - Death rate 0.1%

■ Benefits

- ↓ risk recurrent laryngeal N injury
- ↓ risk hypoparathyroidism
- <5% of recurrences occur in thyroid bed
- >50% recurrences can be treated surgically

Operations...

- Total thyroidectomy
 - ↓ risk of local and regional recurrence
 - Post op radioiodine (¹³¹I) remnant ablation, improved survival
 - 6-8 wks post op: radioiodine body scan
 - If <1% uptake, ok
 - Otherwise need full radioactive iodine inpatient treatment dose for remnant ablation
 - Eliminates 1% anaplastic transformation

Lymph node dissection

Papillary CA

- Prophylactic LN dissection not warranted
- 30-40% incidence of cervical LN mets
- Remove enlarged LN n central or lateral neck
 - Frozen section
- If frozen positive in:
 - Central: central neck dissection
 - Between carotids, hyoid, brachiocephalic vessels
 - Lateral: ipsilateral modified radical neck
 - Anterior and posterolateral to IJV
 - Mastoid superiorly to subclavian vessels inferior
 - Laterally to spinal accessory N (neck levels 2-5)

Follicular CA

- 10% of all thyroid CA
- 3:1 female
- 50 years mean age
- Multicentric and LN mets less common than papillary
- 10% have spread to LN
- FNA not able to differentiate adenoma from carcinoma
- Spread **HEMATOGENOUSLY**
 - Lung and bone most common

Operation

Follicular neoplasm on FNA

- Lobectomy w isthmusectomy
- Intra-operative Frozen section
 - Convert to total thyroidectomy if **capsular** or **vascular** invasion
- Otherwise wait for permanent
 - If carcinoma, take back for Total thyroidectomy
- Post op Radioactive iodine RX

Hurthle Cell Cancer

- Similar clinicopathologic pathway as Follicular
- However
 - <10% take up radioactive iodine
 - >tendency to spread to cervical LN
 - ↑ incidence of distant mets

Post operative

- Thyroid replacement, TSH
- Post op radioiodine RX
 - If >1% uptake on body scan
 - Check TSH post op, >30 ideal
 - Papillary CA >1.5cm
 - +LN mets
 - Invasive follicular/Hurthle cell carcinoma
 - 30mCi I 131 for low risk
 - 100mCi I 131 for higher risk
 - Role of synthetic scan (avoid stopping thyroid)
- Thyroglobulin (glycoprotein)
 - Monitor serum for recurrence
 - If ↑, rule out thyroglobulin antibodies (cause of f+)
- Follow up whole body scans

Medullary Thyroid Cancer (MTC)

- Malignant transformation of neuroectodermally derived parafollicular cells
- 5% of thyroid CA
- 25% hereditary
- FNA
- Immunostaining for **calcitonin**
- **MEN II**
 - Careful pheos
 - **RET protooncogene**
- Spread **Hematogenous**

MEN II

■ MEN IIA

- MTC (100%)
 - calcitonin
- Pheochromocytoma (33%)
 - Urine/serum metanephrines, MIBG
 - RESECT BEFORE THYROID
- Parathyroid Hyperplasia (50%)
 - 3.5 gland resection

■ MEN IIB

- MTC (85%)
 - More aggressive than MEN II A
- Pheo (50%)
- Mucosal neuromas (100%)

Operation MTC

- Total thyroidectomy w central node dissection
 - 75% with involved nodes
- NOT amenable to post op radioiodine
- Serum calcitonin
- U/S

Anaplastic Carcinoma

- Rare, 2-4 % of all thyroid CA
- Rapid expanding mass
- Elderly
- Tumor necrosis
- Common: invasion to adjacent structures
- FNA
- 5 year survival: 3%
- No good RX
 - Surgery, radiotherapy, chemo
 - ↑ recurrence
- ↑ survival if complete resection (rare to perform)
- Surgery for tracheal compression for relief

Lymphoma

- <1%
- Non-Hodgkins, B cell type
- Often w Hashimotos thyroiditis
- Female>Male
- Painless enlarging neck mass
- FNA
- Surgical BX may be required
- Resection rarely needed
- **Radiation PLUS chemo**
- 5 year survival 50-70%
- Poor prognosis
 - >10cm, dysphagia, mediastinum involved



HYPERTHYROIDISM

Hyperthyroidism

- Excess thyroid hormone
- Medical treatment
 - Thionamide inhibition
 - Radioiodine ablation
- Surgical treatment
 - Graves (10% Surgically treated)
 - Toxic multinodular goiter
 - Toxic solitary nodule

Hyperthyroidism

■ Symptoms

- Fatigue
- Wt loss
- Diaphoresis
- Palpitations
- Heat intolerance
- Muscle weakness
- Insomnia
- Diplopia
- Inc appetite
- Dyspnea
- nervousness
- Irritability
- Hair loss
- Diarrhea
- Irregular menses
- Emotional lability

Hyperthyroidism

■ Physical Findings

- Goiter, firm, diffuse
- Tachycardia
- Tremor
- Stare, lid lag
- Proptosis
- Exophthalmos
- Keratitis/conjunctivitis
- Chemosis
- Periorbital edema
- ophthalmoplegia
- Hyperreflexia
- Hyperpyrexia
- Flow murmur
- Gynecomastia
- Splenomegaly
- Thin skin/dermopathy
- Leg swelling
- Pretibial edema

Hyperthyroidism

- Potential Complications
 - Thyroid storm
 - Cachexia
 - Psychosis/delirium
 - Arrhythmias
 - CHF
 - Jaundice
 - Osteoporosis
 - Infertility/spontaneous abortion

Differential diagnosis

Hyperthyroidism

- Graves
- Toxic multinodular goiter (plummers dz)
- Toxic adenoma
- Metastatic thyroid CA
- Painful, subacute thyroiditis
- Silent thyroiditis
- Iodine induced
- Ectopic thyroid from struma ovarii
- Excessive pituitary TSH
- Pituitary resistance to thyroid hormone
- Excessive trophoblastic TSH
- Excess hCG from hydatidiform mole/choriocarcinoma
- Factitious

Advantages of surgery

Graves

- Resolution
- Robust cure
- Tissue diagnosis
- Compliance
- Concern for radioactivity
- Pregnancy
- Youth
- Salvage
- Cosmesis
- Cost
- Thyroid Storm
- Amiodarone induced
- Ophthalmopathy

Disadvantages of Surgery

Graves

- Nerve injury
- Parathyroid compromise
- Bleeding, infection
- Hypothyroidism
- Anesthesia
- Scar
- Cost

Preoperative preparation

Graves

- Inhibit organification of I & coupling of iodthyronine
 - Propylthiouracil (PTU)
 - Methimazole (Tapazole)
 - Carbimazole
- BHCG (pregnancy)
- Calcium (concurrent hyperpara)
- Wait for Euthyroid (3-4 wks)
 - T3 (triiodothyroxine)
 - T4 (thyroxine)
 - TSH (need not normalize)
- Beta blockade for symptoms
 - Propranolol also inhibit T4 to T3
- Iopanoic Acid
 - Inhibit T4 to T3
- Iodine (SSKI or Lugol's)
 - Inhibits release of T4 and T3, wait til euthyroid

Operation: Graves

- Total thyroidectomy
 - Hypothyroid post op
 - Almost no recurrence
- Bilateral subtotal
 - Recurrence up to 70%
 - ↓Nerve & parathyroid injury
- Unilateral total and contralateral subtotal
 - Leave about 4 grams of tissue

Toxic Multinodular Goiter (TMG)

- Same medical options as in Graves
- Thyroxine suppression of TSH not favored
- Radioiodine
 - Poor surgical candidates
 - Elderly
- Surgery
 - Mainly role for toxic and hot nodules
 - Same options as in Graves
 - Less chance of recurrence if tissue left

Toxic Solitary Nodule (TSN)

- Most are follicular, <1% carcinoma
- Debate about suppression
 - Ideal for TSH >1
 - Thyroid levels must be normal or low
- FNA: inconclusive treat as CA
- If continues to grow (>3cm) or becomes worrisome:
 - Lobectomy w Frozen
- Role of radioiodine
 - Poor surgical candidates
 - Not worried about CA
 - Relapse common, up to 50%
- Surgery or Radioiodine preferred over inhibition
- Nodectomy NOT RECOMMENDED

Recurrent Hyperthyroidism

- Up to 12% nerve injury in re op
- Lateral approach
 - Strap muscle mobilized away from SCM
- Early identification of RLN



THYROIDITIS

Thyroiditis

- Inflammation of thyroid gland
 - Chronic Lymphocytic (Hashimoto's)
 - Subacute Granulomatous (de Quervain's)
 - Subacute lymphocytic (painless/postpartum)
 - Acute suppurative (acute bacterial)
 - Invasive fibrous (Riedel's)

Chronic Lymphocytic: Hashimotos

- Most common thyroiditis and hypothyroid in U.S.
- Associated w other autoimmune disorders
 - RA, SLE, Sjogrens
- 95% Female
- Most asymptomatic
- 5% early thyrotoxicosis
- Lymphoma risk
- Diagnosis
 - Diffuse, enlarged, firm
 - ↑Thyroglobulin
 - ↑thyroid microsomal antigen
 - thyrotropin receptor
- TX: non surgical
 - Surgery for nodules or goiter as discussed previously

Subacute Granulomatous: deQuervain's

- Giant cell thyroiditis
- Painful
- Antibodies not elevated
- Viral etiology
- Hyperthyroid symptoms
- Most return to euthyroid 6 m
- ↑ ESR, ↓RAIU, ↑T4 and T3, low to no TSH
- BX rarely needed
- Beta blocker, levothyroxine 3-6m, NSAIDs, rare use of steroids for thyroid and neck pain

Subacute Lymphocytic Thyroiditis

- Postpartum vs Silent
- Autoimmune etiology invoked
- Symptoms similar to deQuervain's
 - But pain unusual
 - ESR normal
- Beta blockers, thyroxine

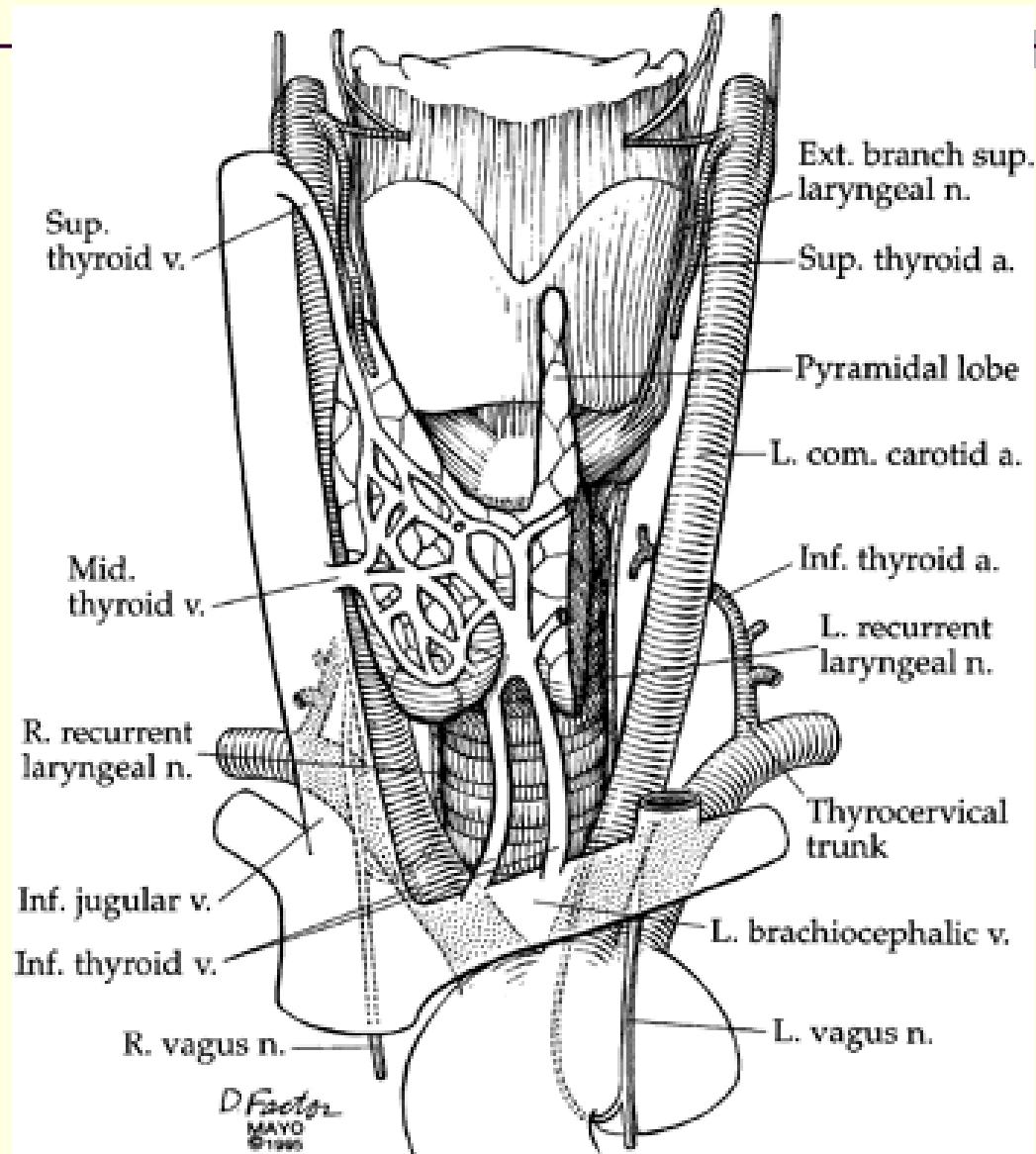
Acute thyroiditis

- Infectious, bacterial
- Rare
- 90% w pyriform sinus fistula (L>R)
 - Prone to repeated infection
- Pain, tender, fever
- Staph, Strep
 - ABX
- fungal/mycobacterium/parasite/AIDS

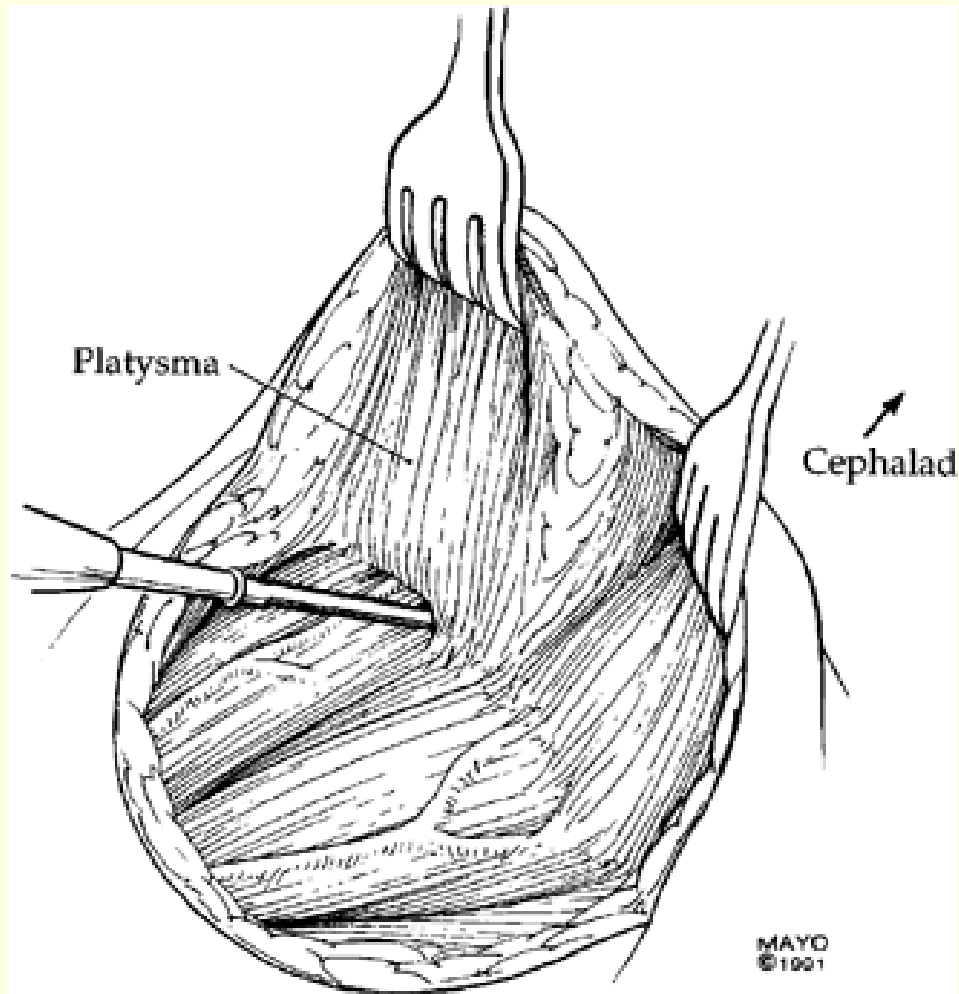
Invasive Fibrous Thyroiditis: Riedel's

- Rare
- Unclear etiology
- Extrathyroidal fibrosis seen
- F>M
- Firm, fixed, woody mass
- Compressive symptoms
- Biopsy: rule out CA
- Steroids first, surgery to help symptoms
 - Surgery rarely helps
 - Tamoxifen

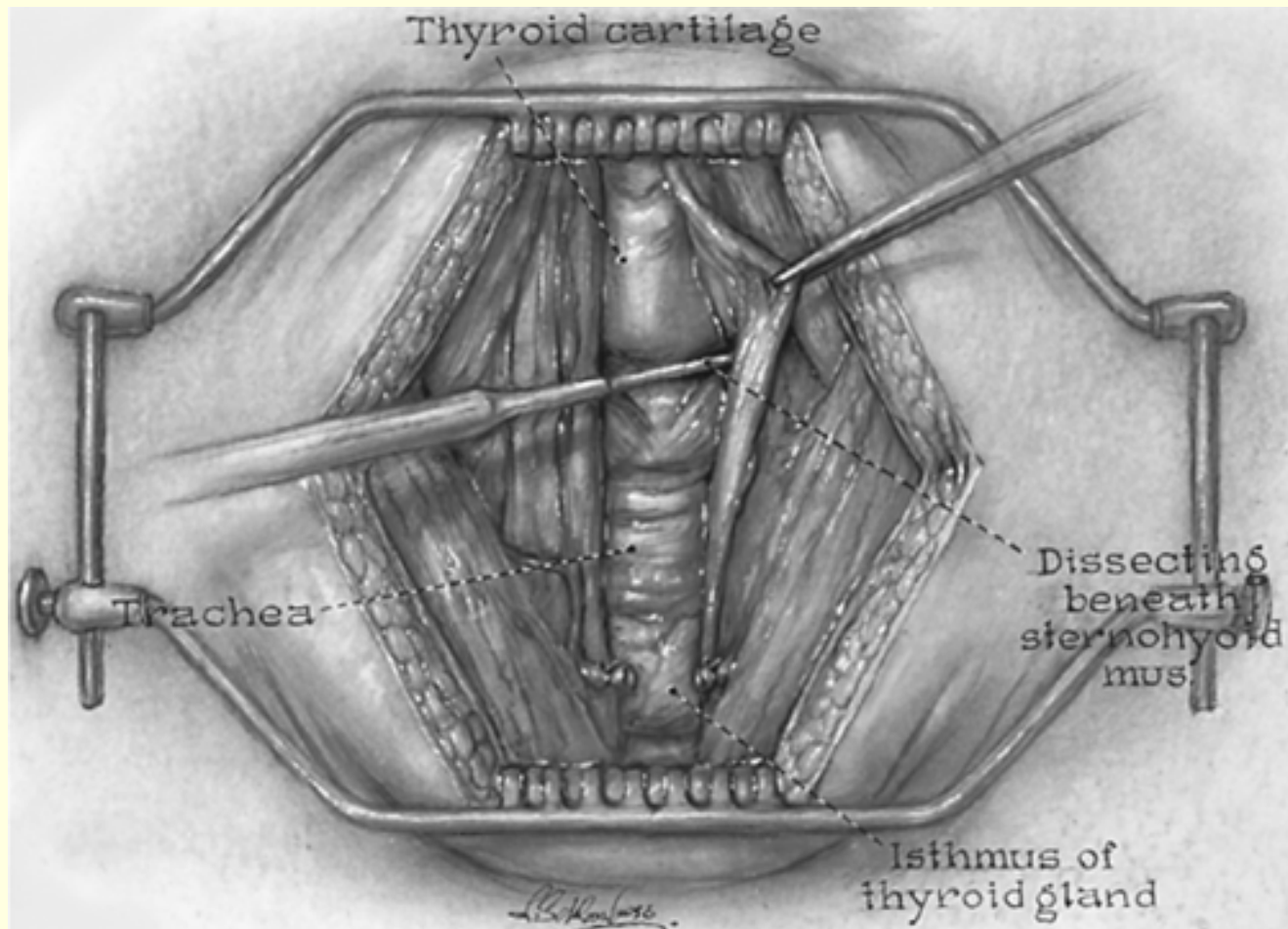
Thyroid Vascular Anatomy



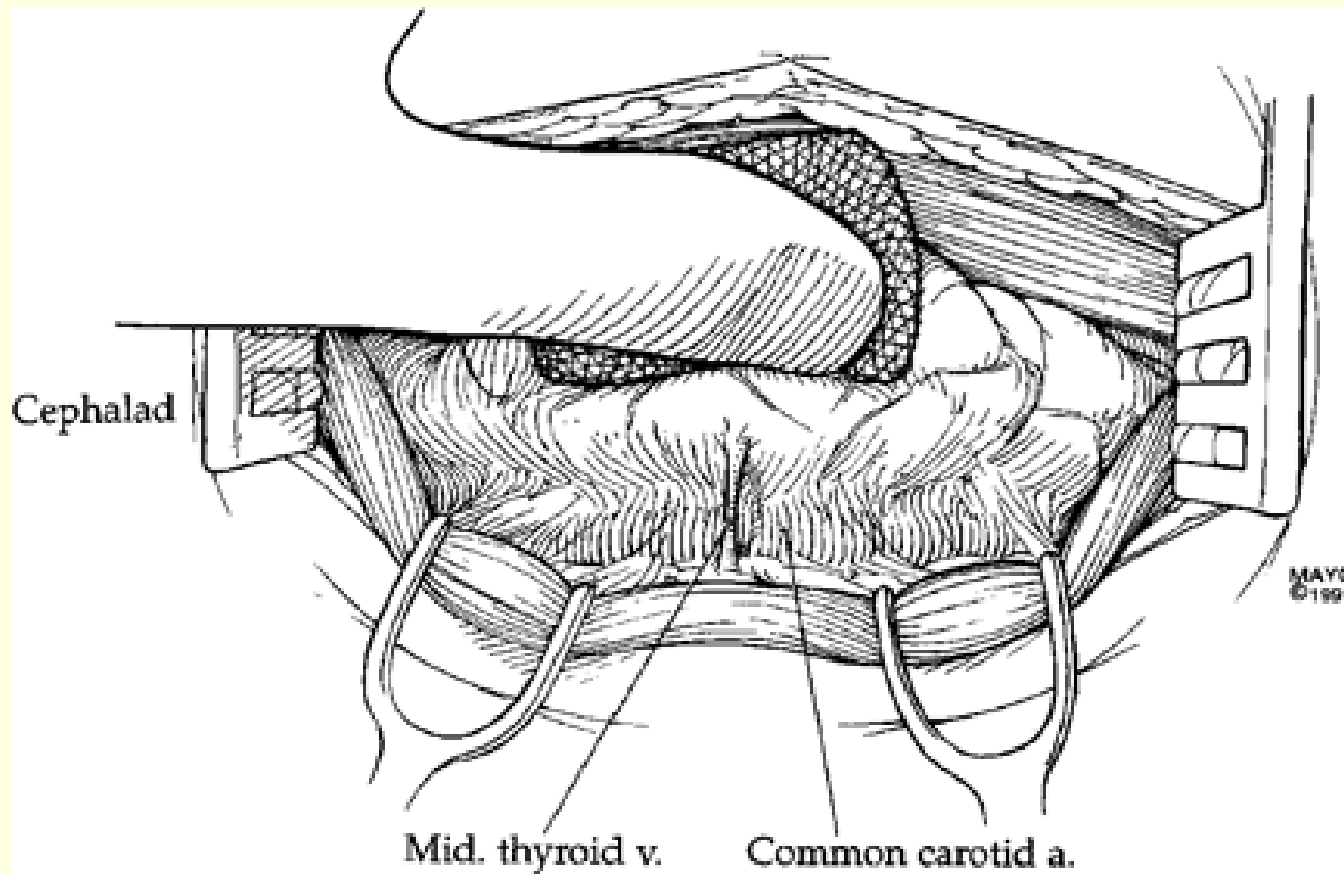
Thyroid Surgery



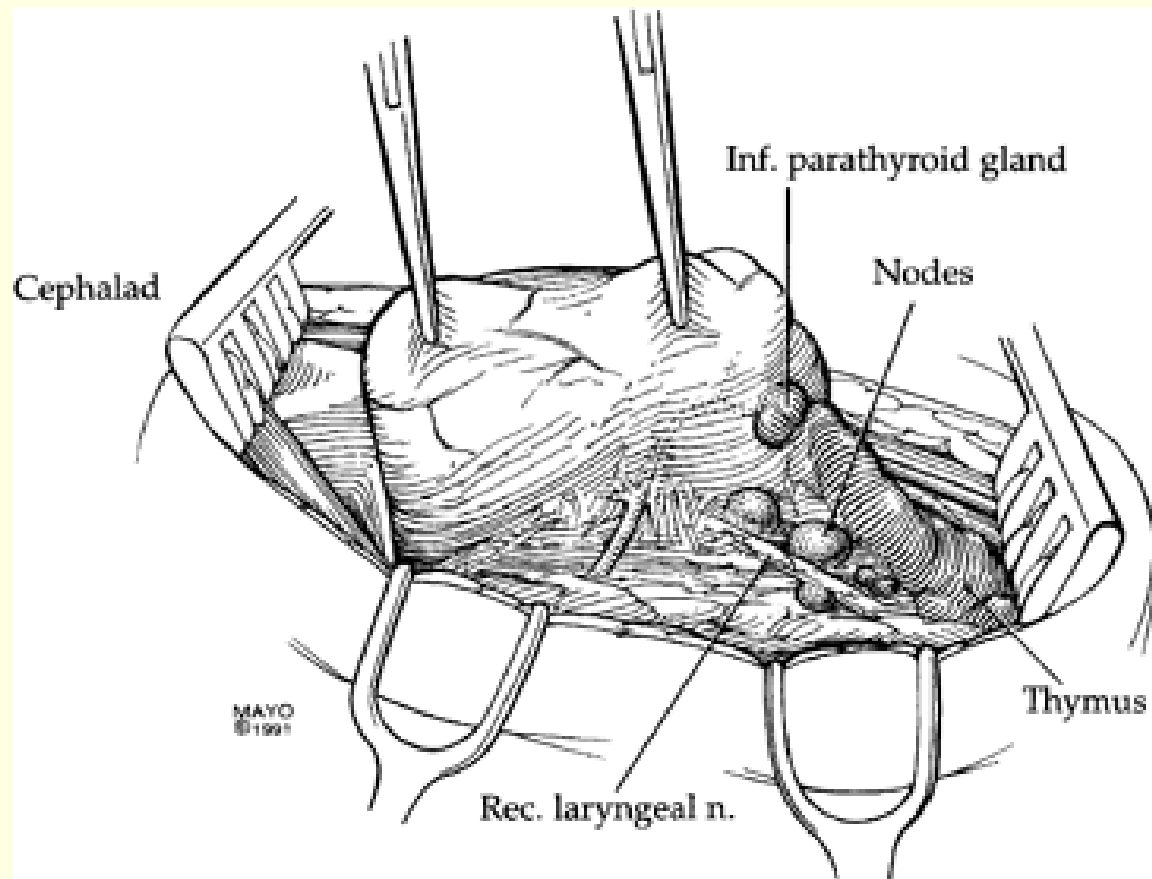
Strap Muscles

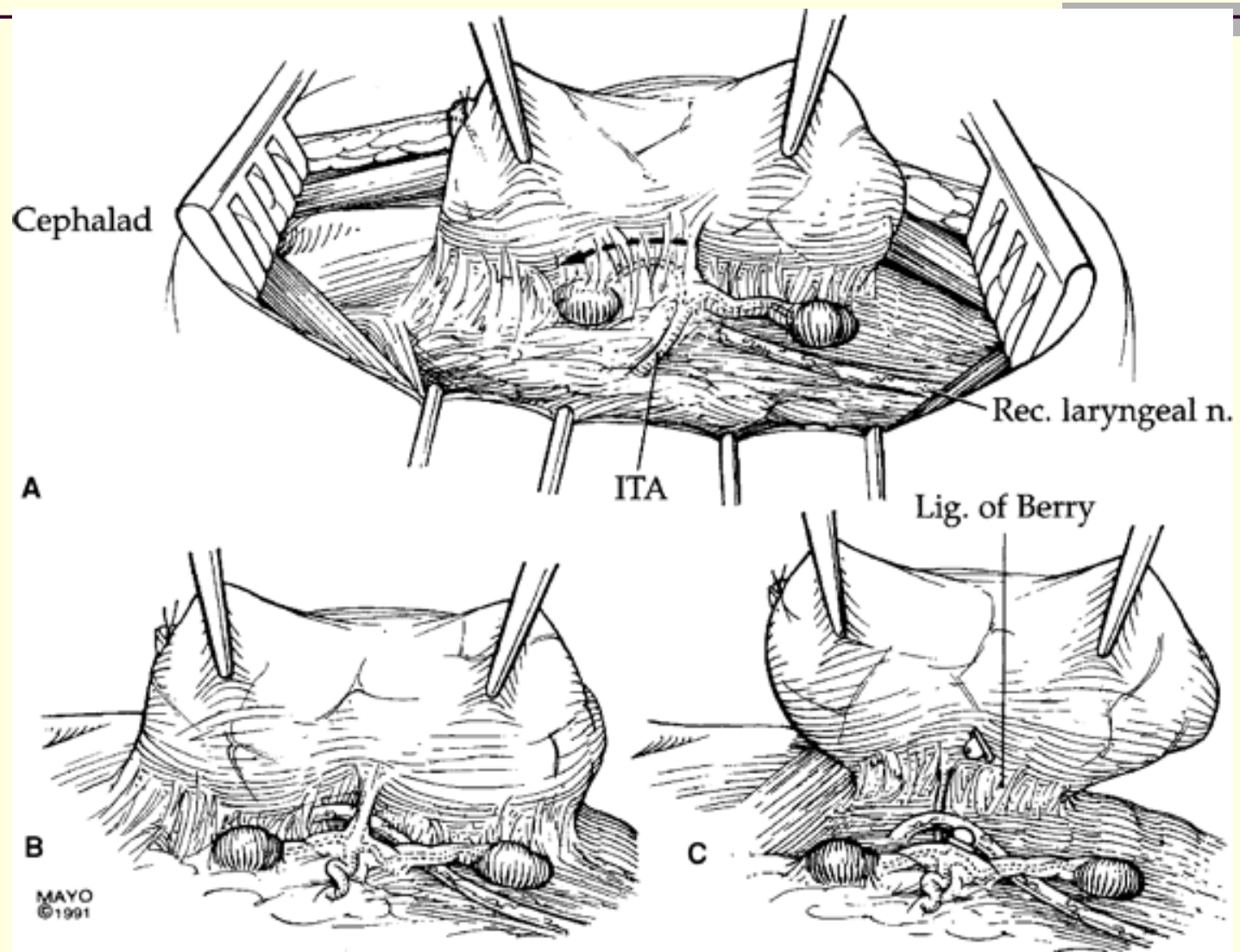


Thyroid: Lateral dissection

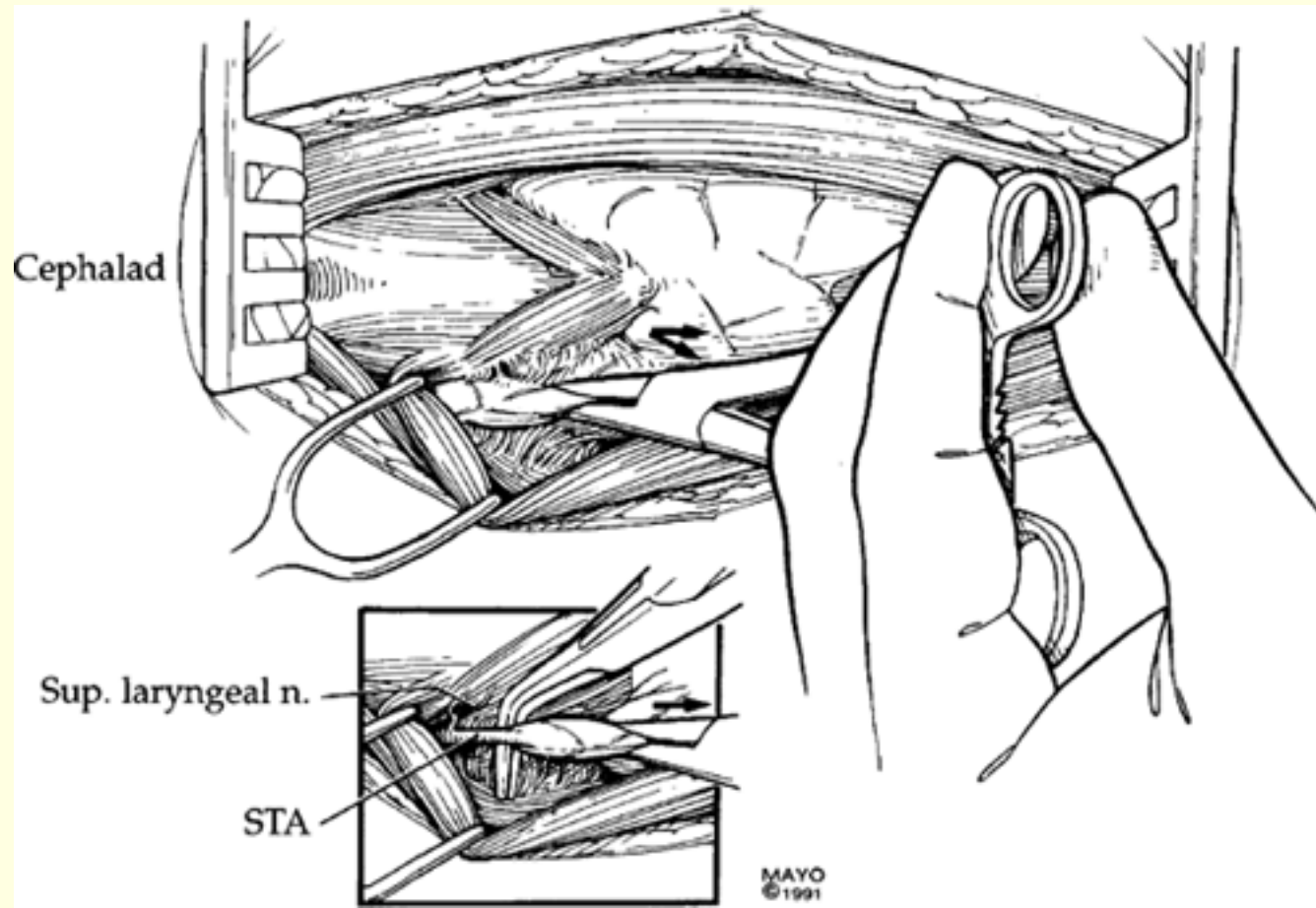


Thyroid: Rec. laryngeal N.

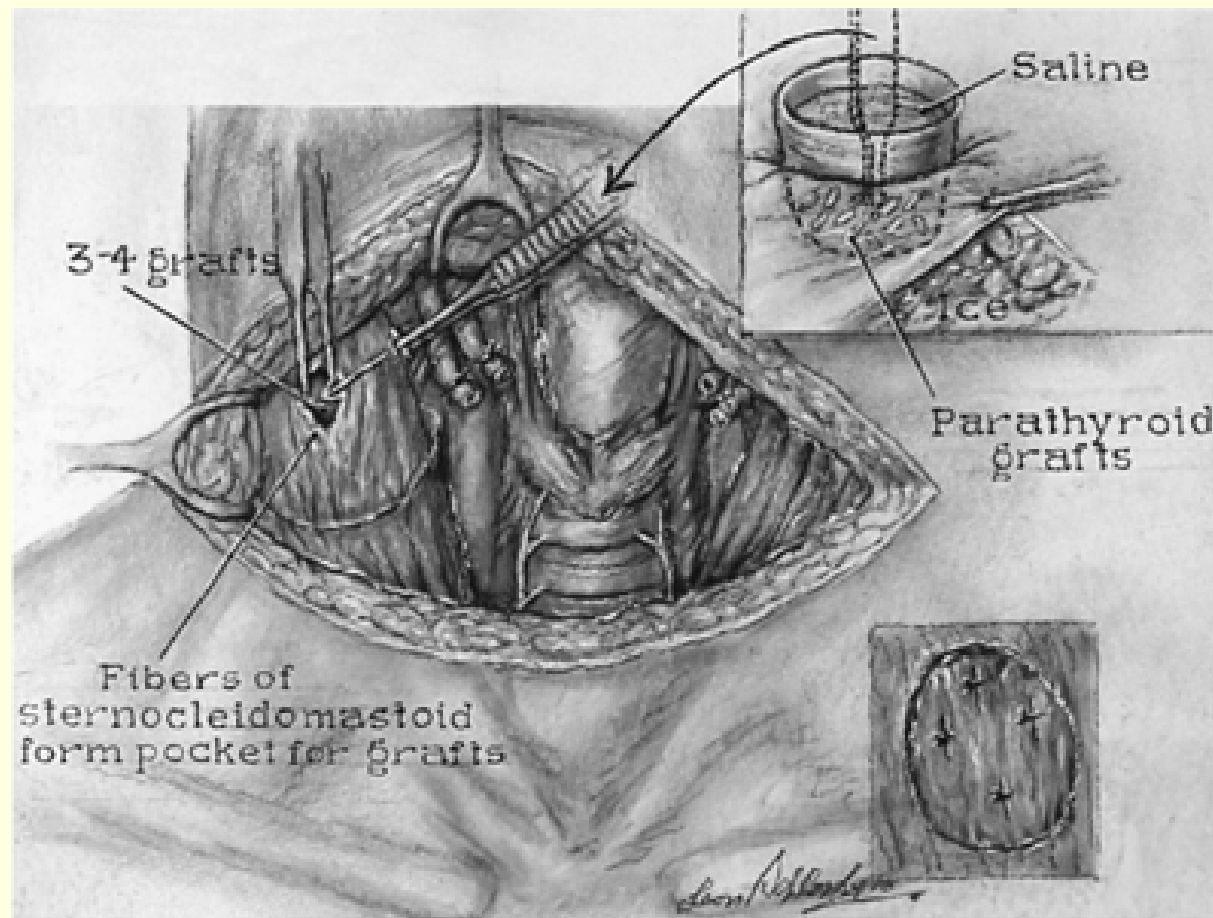




Superior thyroid Artery



Parathyroid Autotransplant





THE END